

**Yuliya Salmeron, DMD**  
**Zhangrui (Zac) Liang, DDS**  
 Root Canal Specialist

Patient \_\_\_\_\_ Tooth # \_\_\_\_\_  
 Referring Doctor \_\_\_\_\_ Date \_\_\_\_\_  
 Patient Contact \_\_\_\_\_

**Reason For Referral**

- Consultation
- Root Canal Treatment
- Retreatment
- Apicoectomy

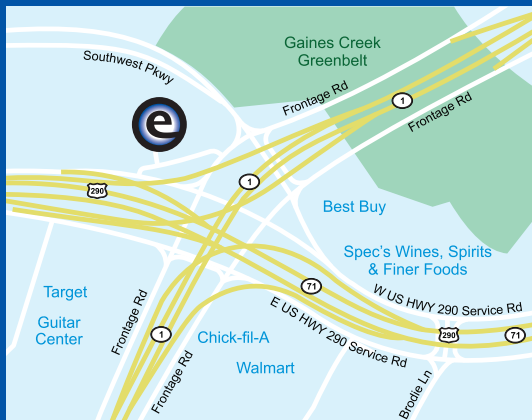
**This Tooth**

- Has Pain
- Has a carious pulp exposure
- Apical Radiolucency
- Previous Root Canal Treatment
- Trauma / Fracture

**After Root Canal Treatment**

- Temporary Filling
- Core Build-Up
- Post / Core
- Leave Post Space
- Restore Access Through The Crown

Comments: \_\_\_\_\_  
 \_\_\_\_\_  
 \_\_\_\_\_



**512.675.3636**

[www.EdgeEndodontics.com](http://www.EdgeEndodontics.com)

[info@EdgeEndodontics.com](mailto:info@EdgeEndodontics.com)

**5100 W Highway 290**  
**Bldg 2, Suite 220**  
**Austin, TX, 78735**

